

# Effect of antibacterial photodynamic therapy in the treatment of pyoinflammatory diseases of the maxillofacial region in infants.

Eshonkulov Sh.B., Fozilov M.M., Kurbanov Sh.Sh.

Department of surgical dentistry and dental implantology, Tashkent state Dental Institute.

**Contact information:** Shukhrat Bunyodovich Eshonkulov, Tashkent state dental Institute, 103 Makhtumkuli street, Tashkent, Republic of Uzbekistan, 100047, shuxrat\_b\_eshonkulov@yahoo.com,

<https://doi.org/10.5281/zenodo.5774316>

**Abstract:** The article presents an effect of antibacterial photodynamic therapy in the treatment of pyoinflammatory diseases of the maxillofacial region in infants. The data on the immune system of the child's body are taken into account when prescribing antibacterial photodynamic therapy.

Treatment of purulent - inflammatory diseases of the maxillofacial region in children continues to be one of the most pressing problems of modern maxillofacial surgery. The number of cases of a sluggish protracted course of inflammatory processes with a tendency to chronicity and the development of complications has increased. This circumstance is explained by many reasons: the irrational use of antibiotics in the treatment of acute purulent inflammatory diseases of the maxillofacial region. Photodynamic antibacterial therapy is a new direction of the quantum effect of the optical range on biological tissues by stimulating a photosensitizer with the production of reactive oxygen species.

**Keywords:** antibacterial photodynamic therapy, infants, pyoinflammatory diseases of the maxillofacial region.

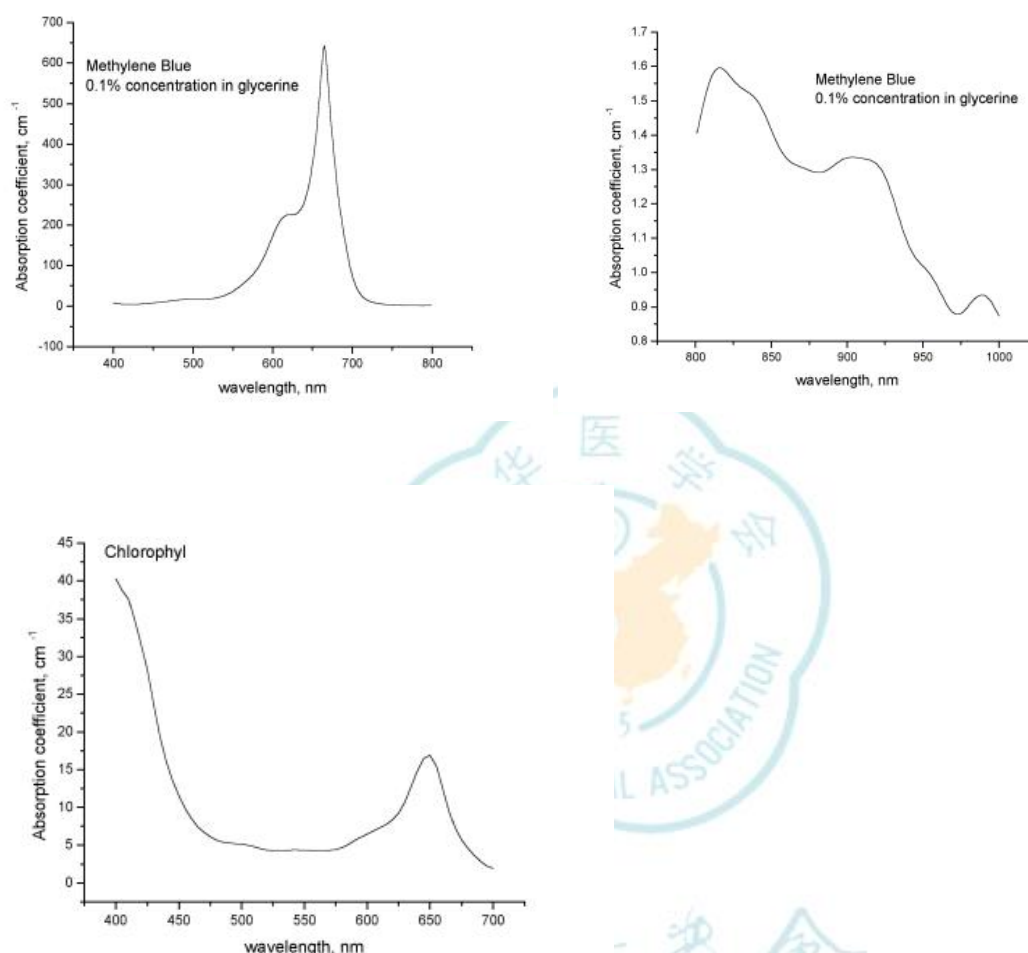
## 1. Introduction

Treatment of purulent - inflammatory diseases of the maxillofacial region in children continues to be one of the most pressing problems of modern maxillofacial surgery. The urgency of the problem is determined not only by the frequency of non-odontogenic inflammatory diseases in young children, but also by changes in the clinical course of the disease itself in recent years. Despite the development of new methods of combating purulent infection, the number of patients with inflammatory diseases has an aggressive tendency to increase and the appearance of formidable complications. The number of cases of a sluggish protracted course of inflammatory processes with a tendency to chronicity and the development of complications has increased. This circumstance is explained by many reasons: the irrational use of antibiotics in the treatment of acute purulent inflammatory diseases of the maxillofacial region. This led to a change in the qualitative composition of the microflora. A significant number of low-manifest, erased forms have appeared, leading to an erroneous opinion about the nature of the inflammatory process. At the same time, the course of inflammatory processes increased, giving complex complications. Recently, self-medication with antibacterial drugs at home has been observed, and this action is far from safe, which can lead to sad consequences for the patient. In conditions of insufficient body defenses, even the most modern antimicrobial therapy will not give the desired effect.

All of the above convincingly suggests that the problem of treating acute purulent inflammatory diseases of the face in children is urgent and requires the development and implementation of new technologies.

Photodynamic antibiotic therapy is a new direction of the quantum effect of the optical range on biological tissues by stimulating a photosensitizer with the production of reactive oxygen species.

For the purpose of photodynamic effects, pigment-containing pharmacological preparations approved for clinical use were used: a solution of methylene blue and chlorophyll. In fig. 1-3 show the absorption spectra of methylene blue and chlorophyll from which it is clearly seen that the absorption maxima of methylene blue in the red region of the spectrum is in the region from 640 to 670 nm, and in the infrared two peaks from 820 to 830 nm and from 900 to 940 nm. The absorption maximum of chlorophyll is located in the red part of the spectrum 640 - 660 nm.



Thus, if we compare the emission spectra of the LED device and the absorption spectra of the pigments used, it should be noted that the maxima of the absorption spectra of both methylene blue and chlorophyll in the red part of the spectrum coincide with the maximum radiation of the LED device proposed for therapy, but the absorption spectrum of methylene blue is much more intense than the spectrum. chlorophyll, therefore, it should be expected that the antimicrobial photodynamic effect when using methylene blue will be significantly higher than chlorophyll.

## 2. MATERIALS and METHODS

To achieve this aims, we examined and treated 64 children with odontogenic non-phlegmon of the maxillofacial region (aged 1 to 3 years). The children were divided into two groups: - control and - studied. Patients were admitted to the clinic on days 10-14 from the onset of the disease. On the day of admission to the hospital, all patients underwent general clinical examinations with blood tests. On the day of hospitalization, purulent foci were opened under anesthesia, the wound was washed with antiseptic solutions and drained. All patients underwent traditional complex drug treatment - antibiotics, desensitizing drugs, detoxification, symptomatic, restorative therapy. After the operation, the children of the control group underwent traditional dressing by washing the wound with antiseptic solutions.

The study group received antibacterial photodynamic therapy after surgery.

For APDT, a swab soaked in a dye (in this case, methylene blue 0.01%) was left in the wound for 10-15 minutes. After that, the operating wound was irradiated for 5 minutes using the FDU-1 laser apparatus. The wound was closed with an aseptic dressing. This procedure was carried out on days 1.3 and 5.

In the control group, after surgery, purulent discharge was discharged from the wound for 3-5 days. By 5-7 days after the operation, the discharge from the wound decreased. The edema persisted for 5-7 days. Soreness in the area of the surgical wound persisted for up to 3 days. Patients were discharged on the 8-9th day.

In patients who were in the study group, the purulent discharge became much less on the 2nd day. The edema in the area of the postoperative wound decreased by 3 days. Soreness became much less for 2 days. The patients after APDT application on the next day began to actively eat and sleep well. The patients were discharged on days 5-6 in satisfactory condition.

To prove efficacy, we used a scorecard of clinical signs of the inflammatory process before and after the use of antibacterial photodynamic therapy.

Table 1. The map of the point assessment of the clinical signs of the purulent-inflammatory process of the maxillofacial region in young children.

		Signs	Points
Common signs	1	Weakness, malaise	1
	2	Sleep disturbance	1
	3	Excitement, restlessness	1
	4	Loss of appetite	1
	5	Body temperature 36.6-36.9C	1
	6	37.0-37.9C	2
	7	38.0C	3
Local signs	8	Collateral edema	1
	9	Inflammatory infiltrate	1
	10	Hyperemia of the skin	1
	11	Discharge of pus	1

Table 2. According to age criteria, children were divided into 3 groups: children under 1-year-old, from 1 to 2 years old, from 2 to 3 years old. All signs of the disease were summarized.

		Age groups	0-1 years old (n=14)	1-2 years old (n=31)	2-3 years old (n=19)	Total (n=64)
		Signs				
Common signs	1	Weakness, malaise	12	27	14	53
	2	Sleep disturbance	13	30	15	58
	3	Excitement, restlessness	13	25	17	55
	4	Loss of appetite	14	28	18	60
	5	Body temperature 36.6-36.9C	4	10	8	22
	6	37.0-37.9C	7	13	7	27
	7	38.0C	3	8	4	15
<b>TOTAL</b>			<b>66</b>	<b>141</b>	<b>83</b>	<b>290</b>
Local signs	8	Collateral edema	14	31	19	64
	9	Inflammatory infiltrate	14	31	19	64
	10	Hyperemia of the skin	13	29	18	60
	11	Discharge of pus	14	31	19	64
<b>TOTAL</b>			<b>55</b>	<b>122</b>	<b>75</b>	<b>252</b>

Table 3. Ball score for the dynamics of changes in clinical signs of purulent inflammatory diseases of the maxillofacial region in young children with traditional treatment and with the inclusion of APDT.

		Age groups Signs	With traditional treatment (n=32)			With traditional treatment with APDT (n=32)		
			At admission	3 days	6 days	At admission	3 days	6 days
Common signs	1	Weakness, malaise	27	17	5	26	10	-
	2	Sleep disturbance	30	10	2	28	5	-
	3	Excitement, restlessness	27	15	3	28	7	-
	4	Loss of appetite	30	18	3	30	7	1
	5	Body temperature 36.6-36.9C	11	11	11	11	11	11
	6	37,0-37,9C	13	5	2	14	2	-
	7	38,0C	8	4	-	7	-	-
<b>TOTAL</b>			<b>146</b>	<b>80</b>	<b>26</b>	<b>144</b>	<b>42</b>	<b>12</b>
Local signs	8	Collateral edema	32	25	12	32	12	3
	9	Inflammatory infiltrate	32	18	3	32	10	-
	10	Hyperemia of the skin	30	27	8	30	14	1
	11	Discharge of pus	32	28	8	32	15	4
<b>TOTAL</b>			<b>126</b>	<b>98</b>	<b>31</b>	<b>126</b>	<b>51</b>	<b>8</b>

The data given in the table shows the effectiveness of antibacterial photodynamic therapy in purulent-inflammatory diseases of the maxillofacial region in young children.

Table 4. Dynamics of indicators of peripheral blood

Significative	Before treatment	After treatment
Erythrocytes, T / L	4,27 + 0,062	4,04 + 0,064 *
Hemoglobin, g / l	133,7 + 2,58	121,9 + 2,15 *
Leukocytes, G / L	5,59 + 1,64	5,55 + 1,76
Eosinophils,%	3,65 + 0,68	2,77 + 0,39
Rod neutrophils,%	2,00 + 0,30	1,92 + 0,23
Segmented neutrophils,%	39,46 + 1,36	42,92 + 1,82 *
Lymphocytes,%	47,04 + 1,59	44,27 + 1,81
Monocytes,%	6,65 + 0,59	7,85 + 0,69
ESR, mm / h	5,62 + 0,61	4,42 + 0,56

Erythrocytes, T / L

After the photodynamic therapy in patients on the 10th day, a slight but significant decrease in the content of erythrocytes and hemoglobin is noted, which indicates an increase in LPO processes caused by an increase in the intensity of photochemical reactions in the presence of photosensitizers (hemoglobin + methylene blue).

Patients also have a significant increase in the number of segmented neutrophils, this fact is also an indirect sign of activation of the microphage link of nonspecific resistance of the organism (table 4). The data in the table also shows that the ESR response tends to decrease, which is a favorable prognostic sign.

### 3. Conclusions:

1. Thus, the presented data convincingly prove the high clinical efficacy of antibacterial therapy based on photodynamic effects caused by the simultaneous action of a physical and chemical factor on the pathogenic microflora.

2. Based on the results obtained, it can be concluded that photodynamic therapy has a pronounced antimicrobial effect. A beneficial advantage of photodynamic effects is the possibility of local selective damage to microbial cells located both superficially and in intercellular spaces, without side effects on the surrounding tissues and microflora of neighboring zones. This effect makes it possible to avoid long-term use of antibacterial drugs and prevent negative effects after antibacterial therapy.

### References:

1. Vasiliev, N. E. Antimicrobial photodynamic therapy / N. E. Vasiliev, A. P. Ogirenko // Laser medicine. 2002. - № 6
2. Duvanskiy, V. A. Photodynamic therapy of purulent, nonhealing wounds and trophic ulcers / V. A. duvanskiy, P. I. Tolstykh, M. W. Karabaev, M. P. Thick // Manual for doctors. M.: 2001.
3. Isaev, V. M. experience in the treatment of chronic sinusitis using photodynamic therapy / M. V. Isaev, A. N. Nasedkin, A. V. Reshetnikov et al. // Laser medicine. 2004. - 8(3).
4. Koraboev, U. M. Studying the activity of photodynamic therapy in an experiment / U. M. Koraboev, M. P. Tolstykh, V. A. Duvansky, D. N. Usmanov // Laser Medicine. 2001. - №5(2).
5. Azimov M. I., Kamalova F. R. " Improvement of treatment and prevention of complications of acute odontogenic periostitis of the jaws in children»//Tashkent-2010.15. Mosolov DV. Peculiarities of medical tactics at rendering of the stomatologic help to patients of elderly and senile age depending on reactance of vegetative nervous system: Author. dis. Cand. honey. sciences'. Moscow. 2016;24.
6. Paulo Malo etc. Short implant placed one stage in maxillae and mandibles Clin Implant Dent Relat Res; 2007.
7. Vuraki NK. Improving the effectiveness of orthopedic treatment of senile patients with complete absence of teeth: abstract. Cand. Honey. Sciences'. Moscow. 2011;24.
8. Barannikov AC, Leanna SA. Prosthesis with complete loss of teeth supported by endosseous implants. Modern Stomatology. 2015;6:42-44.