



Complications After Wisdom Tooth Extraction in The Upper and Lower Jaw

OPEN ACCESS

SUBMITTED 17 December 2024
ACCEPTED 19 January 2025
PUBLISHED 21 February 2025
VOLUME Vol.05 Issue02 2025

COPYRIGHT

© 2025 Original content from this work may be used under the terms of the creative commons attributes 4.0 License.

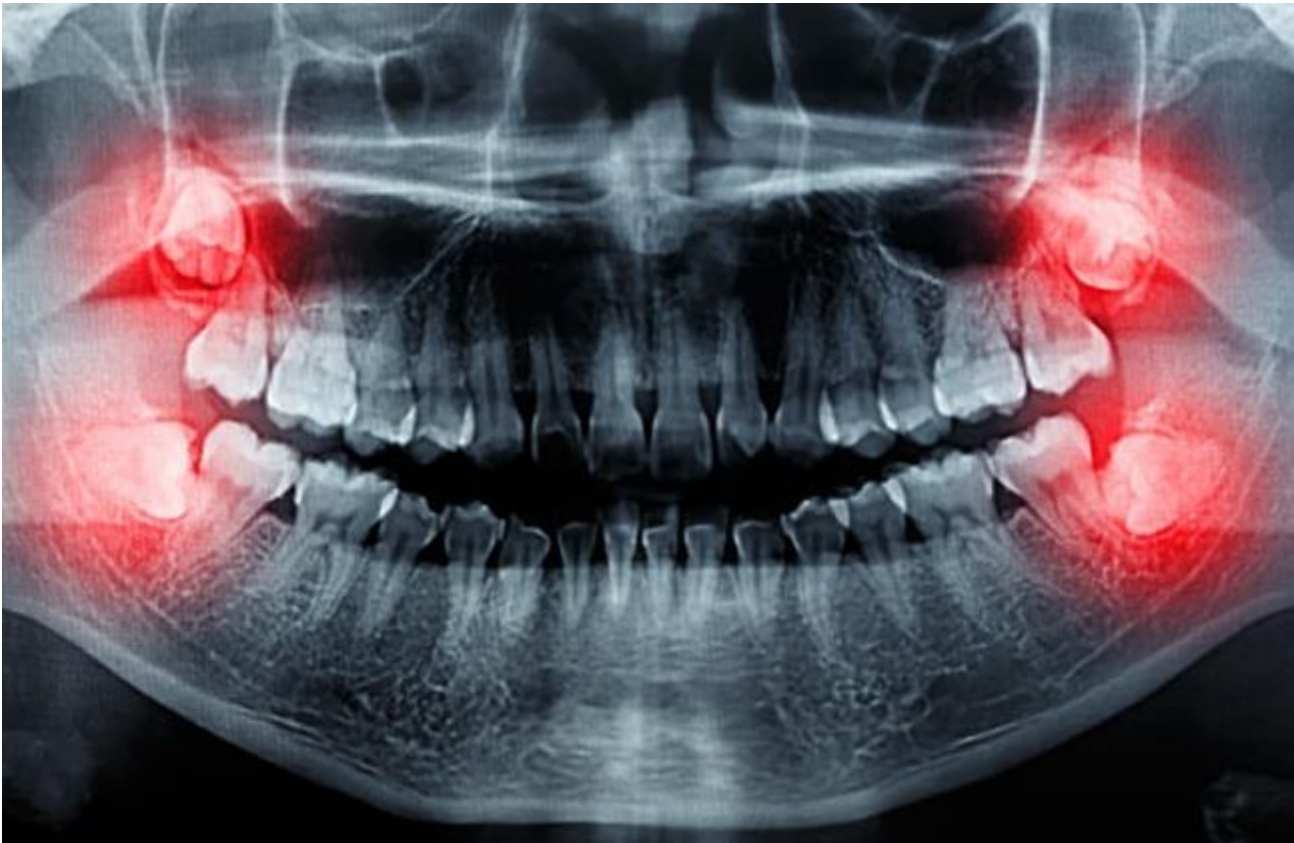Chakkanov Fakhritdin Khusanovich

Assistant Department of orthopedic dentistry, Samarkand State Medical University, Samarkand, Uzbekistan

Abstract: The more complicated the operation and the worse the condition of the wisdom teeth, the higher the likelihood of postoperative complications. Even the most experienced dentist cannot guarantee their complete absence, since certain negative consequences are practically mandatory and are considered the norm. But there are also specific possible complications that arise due to the patient's fault in the postoperative period or due to the inexperience of the doctor.

Keywords: Wisdom Tooth, Upper and Lower Jaw.

Introduction: The more complicated the operation and the worse the condition of the wisdom teeth, the higher the likelihood of postoperative complications. Even the most experienced dentist cannot guarantee their complete absence, since certain negative consequences are practically mandatory and are considered the norm. But there are also specific possible complications that arise due to the patient's fault in the postoperative period or due to the inexperience of the doctor.



Indications for the removal of eighth teeth wisdom teeth

Eights begin to grow much later than the rest of the permanent teeth, as a result of which they often do not have enough space in the jaw. The lack of space provokes all kinds of curvature of the roots and crowns. Doctors recommend removing such molars. Here is another list of problems where extraction is indicated.:

A pronounced tilt of the figure of eight towards the seventh tooth or cheek.

Hypercementosis (excessive deposition of secondary cement, in which the tooth root thickens and deforms).

Incomplete tooth eruption or its location in the bone (retention).

Destruction of the crown or the roots of the figure of eight, as well as adjacent teeth (after injury or caries).

Granuloma (granulation in the form of cystic sacs with pus located in the periodontium).

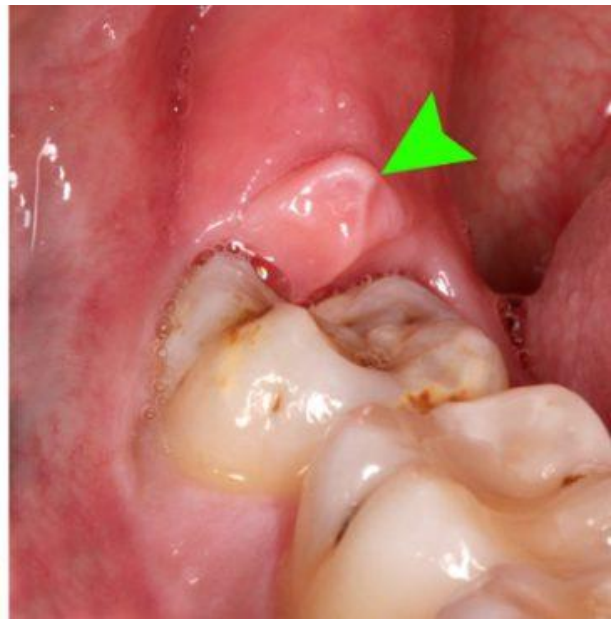
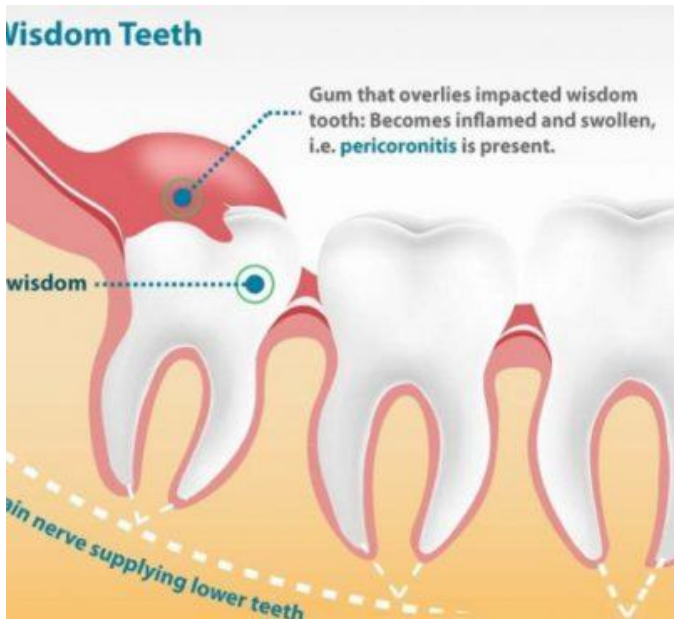
Rotation of the tooth around its axis or horizontal position (dystopia).

Deformation of the roots (they can bend in every possible way, even twist into a spiral or form a 90° angle).

The close location of the roots of the upper eights to the nasal maxillary sinuses.

In the presence of pericoronitis (an acute inflammatory process in the area of the figure of eight, accompanied by pain, increased ESR in blood tests).

An improperly growing 8 tooth can damage the facial nerves and provoke neuritis, which is expressed by sharp pain radiating to the ears, neck, temple, and can lead to facial paralysis.



The occurrence of complications

Figure-of-eight operations are considered complex dental procedures that are caused by:

- difficult access;
- frequent retention;
- unpredictable structure;
- features of the location of the mandibular alveolar nerve.

Such procedures are very traumatic, which creates the prerequisites for the occurrence of complications of general and specific types.

Common

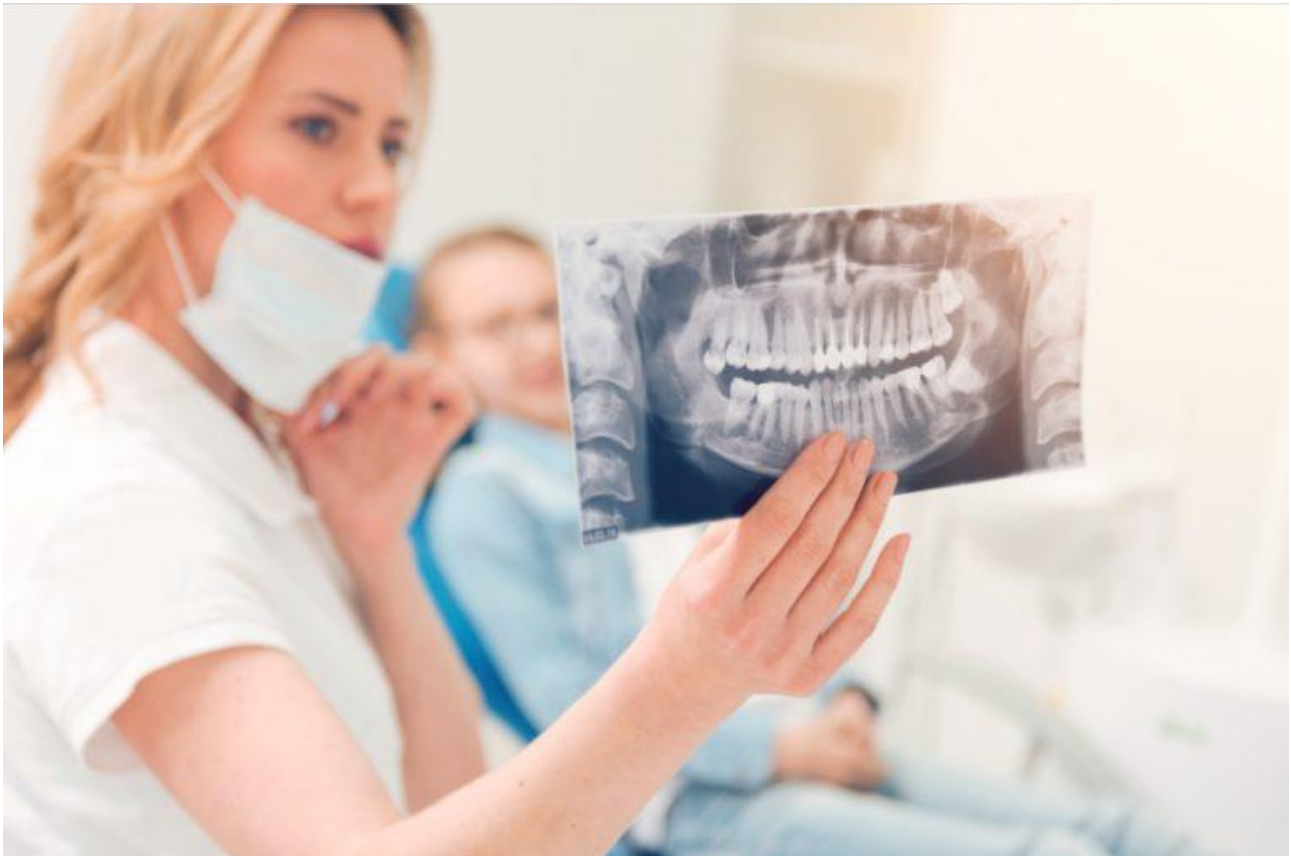The nature of the complications largely depends on the location of the tooth: on the upper or lower jaw. But there are also common complications that occur in almost everyone, regardless of the location of the

figure of eight and its initial condition. The most common common consequences are listed below.

Painful sensations

Approximately 2-3 hours after the extraction of the molar, there will be noticeable pain in the gums. This is a normal body reaction to injury, which is dental surgery. During it, soft tissues are torn or cut, bone is injured (if the tooth is located under it), blood vessels and nerves are disrupted. The painful sensations should disappear completely after 2-4 days, and in some cases they disappear in a few hours. They can be reduced with the help of pain medications prescribed by the dentist.

If the soreness persists, and the cheek is severely swollen, it means that the healing process of the gums is complicated.



Swelling of the tissues of the face and neck

Often, after the extraction of the figure eight, especially retinated, there is swelling of the soft tissues of the gums or cheeks. This is also a reaction to injury, which can be called a normal consequence of a dental procedure. In addition to edema, the following symptoms may occur::

swelling of lymph nodes;

discomfort when swallowing;

painful sensations during mouth movements, radiating into the ear.

Normally, severe edema should go away completely in 2-3 days, and if it does not go away, then we can talk about more dangerous consequences. If the condition worsens every day, breathing difficulties occur, fainting, fever rises and the skin becomes covered with a rash, then such swelling is provoked by allergies and it can lead to anaphylactic shock.

Hematomas

A hematoma due to extraction is usually expressed by a minimal cyanosis of the cheek, which resolves after a few days. But there are situations when the appearance of a bruise is accompanied by severe pain, swelling, and fever. In such a situation, medical care is necessary.

Hematomas form after vascular damage in people with increased capillary fragility, as well as in the presence of hypertension in the patient.

Alveolitis

complications after wisdom tooth extraction

Alveolitis is often provoked by non-compliance with the doctor's recommendations after medical procedures. It is a local inflammation of the gums with the following additional symptoms:

the gum swells, turns red;

there is a local and headache;

sore throat;

fever, muscle aches;

the lymph nodes become inflamed, most often the submandibular.

If there is inflammation, the cause is often the loss of a blood clot from the hole and infection. Various infections that enter the wound if hygiene is not followed can provoke extensive inflammation. In advanced cases, the above complication develops into osteomyelitis, which is expressed by:

increased stable temperature;

poor general health;

severe migraine-like pain;

nausea;

other signs of intoxication of the body.

Increased body temperature

A slight increase in body temperature to 37.5-38 ° C also often occurs in the postoperative period. This

complication occurs due to a reaction to inflammation. The temperature should return to normal within the first day, and if it continues to rise and rise, it means that more serious pathologies have arisen and you need to go to the hospital again.

The bleeding

The dentist will never release a patient with severe bleeding, especially if it is complicated. After removing the figure of eight, the bleeding is stopped in the hospital, and then released home with a gauze swab on the hole. If blood clotting is normal, then the bleeding will stop in 10-15 minutes, after which the tampon must be removed.

Severe prolonged bleeding is provoked by:

rupture of large vessels;

fragility of capillaries;

hypertension.

Damage to the roots of adjacent teeth

Such a complication is extremely rare and only if the patient has not undergone an X-ray diagnosis before the procedure. This procedure is mandatory for all people with indications for the removal of eights and allows you to fully assess the condition, location, as well as other features of the tooth and its roots.

The flux

The flux in the postoperative period develops in cases when the gum is infected due to the fault of the dentist or the patient, after which the infection quickly reaches the periosteum and provokes its inflammation. This complication is not considered normal and acceptable, it must be treated. The main signs of flux:

redness, suppuration, and swelling of the gums;

severe shooting pain;

temperature rise;

weakness.

Others

Among other common complications, the following are most often observed:

displacement of the seventh tooth (2 molars);

mouth tear; gum or cheek cut;

jaw injuries.

In addition, complex extraction of the 8th tooth can cause cyst formation. This is a small neoplasm located at the root of the tooth and filled with fluid. The cyst often serves as an insulator for infected cells from healthy ones. To prevent its appearance, the dentist prescribes antibiotics, and the treatment in this case (if the cyst is located at the roots of the tooth) will be

resection.

On the lower jaw

Standard and non-standard complications after pulling out eights on the lower jaw occur more often than on the upper one. The lower jaw has a number of features, and there are many obstacles in the area of the wisdom teeth.

Nerve damage

The mandibular and lingual nerves are at risk of injury, as they pass close to the wisdom tooth. Such damage causes paresthesia, which is manifested by impaired sensitivity.:

sensory;

painful;

gustatory;

temperature control.

In the most severe cases, nerve damage negatively affects vision, hearing, and also provokes paralysis. Patients compare paresthesia with numbness of the jaw in the area of the removed molar. In most cases, this complication disappears on its own in a few days, but sometimes additional medication is required.

Fracture of the alveolar process

A fracture of the alveolar process of the lower jaw occurs when the dentist incorrectly grips the jaw and exerts more force than necessary. This is an unlikely complication, as the lower jaw is quite strong. The treatment is performed under conduction anesthesia and consists of repositioning and fixing the fragment in the correct position.

Jaw damage

a snapshot of the jaw

Jaw injuries (dislocations and even fractures) are also often caused by the doctor if the tooth is pulled out too intensively or abruptly. During surgery, a significant amount of the mandibular bone has to be removed to provide access to the problematic molar. Because of this, the sections of the jaw are weakened, which increases the risk of fracture if excessive force is applied.

A crack or fracture does not always appear immediately. It happens that the patient notices the first symptoms in the form of pain, swelling, and impaired mobility already at home. Sometimes it takes a week before they appear. Statistics show that jaw injuries during medical procedures account for no more than 0.2% of all fractures.

Soft tissue injuries

By pulling out the molar, the doctor may injure the soft tissues surrounding the molar. It's not just about the gum, but also about the cheek, tongue, and lips.

Injuries are inflicted with dental instruments (scalpel, drill, forceps). The lip is also often injured by the thread used to suture the gums. This is due to the doctor's inattention or the patient's restlessness.

To avoid complications, you need to sit quietly in the dental chair and not distract the doctor.

On the top

The most common complication of the extraction of eights in the upper jaw is a puncture of the base of the maxillary sinus (maxillary sinus).

Puncture of the sinus floor of the upper jaw

The dental roots of molars number three in the upper jaw are located too close to the base of the sinus, and sometimes even grow into it. Chronic inflammation of the periapical tissue provokes resorption of the axillary septum, which causes the roots of the molars to fuse with the mucous membrane inside the sinus. It is most often ruptured during extraction of the right or left tooth. You can notice this complication by the following symptoms::

nasal discharge, bleeding, air bubbles;

Nosebleed from the figure of eight.

In such a situation, urgent medical care is necessary.

CONCLUSION

No one is immune from complications after the extraction of the upper and lower wisdom teeth. It is possible to significantly reduce the likelihood of their occurrence and alleviate the condition in the postoperative period.

It is necessary to choose a dentist carefully before the procedure and follow all the recommendations that he should give after the operation.

REFERENCES

Asrorovna, X. N., Baxriddinovich, T. A., Bustanovna, I. N., Valijon O'g'li, D. S., & Qizi, T. K. F. (2021). Clinical Application Of Dental Photography By A Dentist. The American Journal of Medical Sciences and Pharmaceutical Research, 3(09), 10-13.

Ugli, A. A. A., & Bustanovna, I. N. (2024). STUDY OF THE CONDITION OF PARODONT IN PERIODONTITIS IN FETAL WOMEN. European International Journal of Multidisciplinary Research and Management Studies, 4(05), 149-156.

Kizi, J. O. A., & Bustanovna, I. N. (2024). FAMILIARIZATION WITH THE HYGIENIC ASSESSMENT OF THE CONDITION OF THE ORAL MUCOSA IN ORTHOPEDIC TREATMENT. European International Journal of Multidisciplinary Research and Management Studies, 4(05), 89-96.

Bustanovna, I. N. (2024). Determination of the

Effectiveness of Dental Measures for the Prevention of Periodontal Dental Diseases in Workers of the Production of Metal Structures. International Journal of Scientific Trends, 3(5), 108-114.

Bustanovna, I. N. (2022). Assessment of clinical and morphological changes in the oral organs and tissues in post-menopause women. Thematics Journal of Education, 7(3).

Bustanovna, I. N., & Berdiqulovich, N. A. (2022). ПРОФИЛАКТИКА И ЛЕЧЕНИЯ КАРИЕСА У ПОСТОЯННЫХ ЗУБОВ. JOURNAL OF BIOMEDICINE AND PRACTICE, 7(1).

Bustanovna, I. N. (2024). PATHOGENESIS OF PERIODONTAL DISEASE IN ELDERLY WOMEN. Лучшие интеллектуальные исследования, 21(3), 25-29.

Bustanovna, I. N. (2024). TO STUDY THE HYGIENIC ASSESSMENT OF THE CONDITION OF THE ORAL MUCOSA DURING ORTHOPEDIC TREATMENT. Лучшие интеллектуальные исследования, 21(1), 9-15.

Bustanovna, I. N. (2024). CLINICAL AND LABORATORY CHANGES IN PERIODONTITIS. Journal of new century innovations, 51(2), 58-65.

Bustanovna, I. N. (2024). Morphological Changes in Oral Organs and Tissues in Women after Menopause and their Analysis. International Journal of Scientific Trends, 3(3), 87-93.

Bustanovna, I. N. (2024). Hygienic Assessment of The Condition of The Oral Mucosa After Orthopedic Treatment. International Journal of Scientific Trends, 3(3), 56-61.

Bustanovna, P. I. N. (2024). Further Research the Features of the Use of Metal-Ceramic Structures in Anomalies of Development and Position of Teeth. International Journal of Scientific Trends, 3(3), 67-71.

Bustanovna, I. N. (2024). The Effectiveness of the Use of the Drug "Proroot MTA" in the Therapeutic and Surgical Treatment of Periodontitis. International Journal of Scientific Trends, 3(3), 72-75.

Bustanovna, P. I. N. (2024). Research of the Structure of Somatic Pathology in Patients with Aphthous Stomatitis. International Journal of Scientific Trends, 3(3), 51-55.

Bustanovna, I. N., & Abdusattor o'g, A. A. A. (2024). Analysis of Errors and Complications in the Use of Endocal Structures Used in Dentistry. International Journal of Scientific Trends, 3(3), 82-86.

Bustanovna, I. N. (2024). Complications Arising in the Oral Cavity after Polychemotherapy in Patients with Hemablastoses. International Journal of Scientific Trends, 3(3), 62-66.

Bustanovna, I. N., & Sharipovna, N. N. (2023). Research cases in women after menopause clinical and

morphological changes in oral organs and their analysis. *Journal of biomedicine and practice*, 8(3).

Bustonovna, I. N., & Sharipovna, N. N. (2023). Essential Factors Of Etiopathogenesis In The Development Of Parodontal Diseases In Post-Menopasis Women. *Eurasian Medical Research Periodical*, 20, 64-69.

Fakhriddin, C. H. A. K. K. A. N. O. V., Shokhruh, S. A. M. A. D. O. V., & Nilufar, I. S. L. A. M. O. V. A. (2022). ENDOKANAL PIN-KONSTRUKSIYALARNI ISHLATISHDA ASORATLAR VA XATOLAR TAHLILI. *JOURNAL OF BIOMEDICINE AND PRACTICE*, 7(1).

Очилов, Х. У., & Исламова, Н. Б. (2024). Особенности артикуляции и окклюзии зубных рядов у пациентов с генерализованной формой повышенного стирания. *SAMARALI TA'LIM VA BARQAROR INNOVATSIYALAR JURNALI*, 2(4), 422-430.

Ortikova, N., & Rizaev, J. (2021, May). The Prevalence And Reasons Of Stomatophobia In Children. In *E-Conference Globe* (pp. 339-341).

Ortikova, N. (2023). ANALYSIS OF ANESTHESIA METHODS FOR DENTAL FEAR AND ANXIETY. *Центральноазиатский журнал академических исследований*, 1(1), 8-12.

Ortikova, N. K. (2023). DENTAL ANXIETY AS A SPECIAL PLACE IN SCIENTIFIC KNOWLEDGE. *SCHOLAR*, 1(29), 104-112.

Исламова, Н. Б. (2024). ПАРОДОНТ КАСАЛЛИКЛАРИДА ОРГАНИЗМДАГИ УМУМИЙ ЎЗГАРИШЛАРНИ ТАҲЛИЛИ ВА ДАВОЛАШ САМАРАДОРЛИГИНИ ТАКОМИЛЛАШТИРИШ. ОБРАЗОВАНИЕ НАУКА И ИННОВАЦИОННЫЕ ИДЕИ В МИРЕ, 43(7), 18-22.

Islamova, N. B., & Chakkonov, F. K. (2021). Changes in the tissues and organs of the mouth in endocrine diseases. *Current Issues in Dentistry*, 320-326.

Исламова, Н. Б., & Исламов, Л. Б. (2021). Особенности развития и течения заболеваний полости рта при эндокринной патологии. *ББК*, 56, 76.

Исламова, Н. Б., & Назарова, Н. Ш. (2023). СУРУНКАЛИ ТАРҚАЛГАН ПАРОДОНТИТ БИЛАН КАСАЛЛАНГАН ПОСТМЕНОПАУЗА ДАВРИДАГИ АЁЛЛАРНИНГ ПАРОДОНТ ТЎҚИМАСИНИНГ ДАВОЛАШ САМАРАДОРЛИГИ ОШИРИШ. *ЖУРНАЛ СТОМАТОЛОГИИ И КРАНИОФАЦИАЛЬНЫХ ИССЛЕДОВАНИЙ*, 4(2).

Исламова, Н. Б. (2024). ПАРОДОНТИТ КАСАЛЛИГИДА

Nazarova, N. S., & Islomova, N. B. (2022). postmenopauza davridagi ayollarda stomatologik kasalliklarining klinik va mikrobiologik ko'rsatmalari va

mexanizmlari. *Журнал" Медицина и инновации"*, (2), 204-211.

Nazarova, N. S., & Islomova, N. B. (2022). postmenopauza davridagi ayollarda stomatologik kasalliklarining klinik va mikrobiologik ko'rsatmalari va mexanizmlari. *Журнал" Медицина и инновации"*, (2), 204-211.

Sulaymonova, Z. Z., & Islamova, N. B. (2023, May). TAKING IMPRESSIONS IN THE ORAL CAVITY AND THEIR REDUCTION. In *Conferences* (pp. 21-23).

Sharipovna, N. N., & Bustonovna, I. N. (2022). Etiopatogenetic factors in the development of parodontal diseases in post-menopasis women. *The american journal of medical sciences and pharmaceutical research*, 4(09).

Sarimsokovich, G. M. (2023). LATEST METHODS OF STUDY OF PERIODONTAL DISEASE IN WOMEN. *European International Journal of Multidisciplinary Research and Management Studies*, 3(10), 242-250.

DENTAL PROSTHETICS. *Лучшие интеллектуальные исследования*, 18(4), 31-35.

Содиқова, Ш. А., & Исламова, Н. Б. (2021). Оптимизация лечебно-профилактических мероприятий при заболеваниях пародонта беременных женщин с железодефицитной анемией. In *Актуальные вопросы стоматологии* (pp. 434-440).

Чакконов, Ф. Х. (2021). ЯТРОГЕННЫЕ ОШИБКИ В СТОМАТОЛОГИИ И ИХ ПРИЧИНЫ. In *Актуальные вопросы стоматологии* (pp. 925-930).

ЧАККОНОВ, Ф., САМАДОВ, Ш., & ИСЛАМОВА, Н. (2022). ENDOKANAL PIN-KONSTRUKSIYALARNI ISHLATISHDA ASORATLAR VA XATOLAR TAHLILI. *ЖУРНАЛ БИОМЕДИЦИНЫ И ПРАКТИКИ*, 7(1).

Xusanovich, C. F., Orzimurod, T., Maruf, U., & Ollomurod, X. (2023). PROSTHETICS A COMPLETE REMOVABLE PROsthESIS BASED ON IMPLANTS. *European International Journal of Multidisciplinary Research and Management Studies*, 3(11), 122-126.

Xusanovich, C. F., Sunnat, R., & Sherali, X. (2024). CLASP PROSTHESES—TECHNOLOGY IMPROVEMENT. *European International Journal of Multidisciplinary Research and Management Studies*, 4(03), 152-156.